



PATIENT

Niko Stamos

SPECIES

Canine

BREED

Doberman

SEX

Male Neutered

AGE

3

WEIGHT

88lbs

INTERPRETED BY

Maggie Machen Lamy,
DVM, DACVIM
(Cardiology)

IMAGING PERFORMED BY

HOSPITAL NAME

Mass Veterinary
Services

REFERRING VET

Dr. Masloski

INVOICE

31443

DATE

6/20/23

PRESENTING CLINICAL SIGNS

History: Niko has had genetic testing which revealed him to be heterozygous for the gene that is related to DCM. Niko had a gastropexy for GDV ~ 3 months ago. Niko is eating well with normal activity. He does not have any current C/S/V/D/PU/PD. *Echo NSF (MML 6/2023)

HOLTER MONITOR FINDINGS AND RHYTHM ASSESSMENT

Time analyzed	21:59h
Mean heart rate	65bpm
Maximum heart rate	229bpm
Minimum heart rate	39bpm
VPCs	7 singles
APCs	0

Interpretation: Underlying normal sinus rhythm with appropriate rate variation. Rare (7) single VPCs are seen, which are essentially a normal finding for a 24 hour recording. Occasional sinus pauses while sleeping/bradycardic. Max HR is sinus in origin with excitement.

Rhythm diagnosis: Normal sinus rhythm with rare isolated VPCs (7).

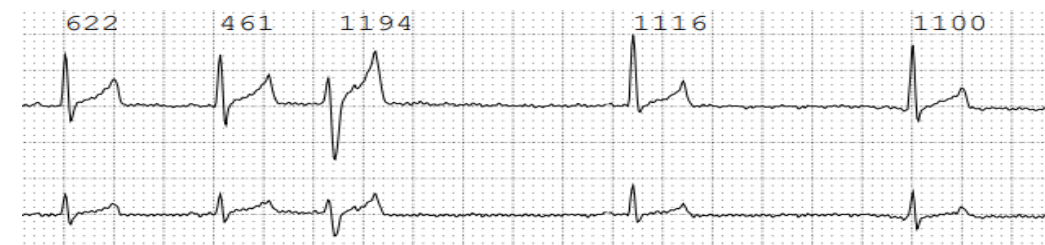
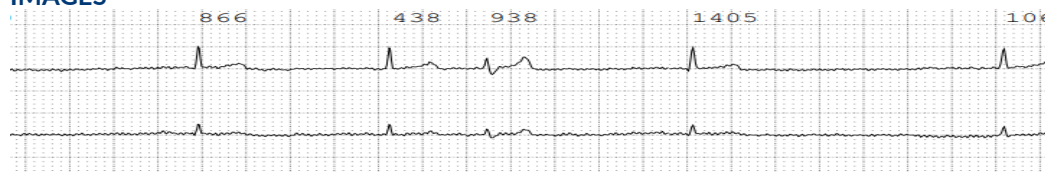
RECOMMENDATIONS

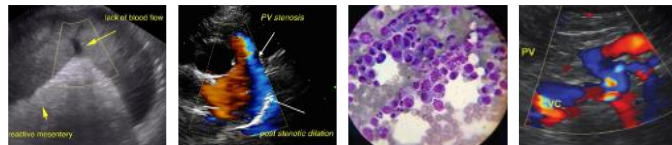
Essentially normal recording. The VPC count is considered normal for a 24 hour period, and is suppressed by sinus node stimulation. The VPCs are monomorphic without markers of malignancy. No significant extra-nodal tachycardias are noted, and no malignant arrhythmias identified. The HR is appropriate as compared to the diary.

No medications are indicated at this time. No evidence of arrhythmogenic form of DCM.

Recheck annually, sooner if clinical signs such as syncope arise.

IMAGES





PATIENT

Niko Stamos

The information and recommendations provided are based on the images presented by the referring veterinarian. No evaluation can be communicated regarding pathology that was not visible in the image/video clips provided.

SPECIES

Canine

Thank you for this referral. If the clinical or image interpretation does not parallel your findings or if I can be of any further assistance please contact me.

BREED

Doberman

Maggie Machen Lamy, DVM

Diplomate of the American College of Veterinary Internal Medicine (Cardiology)

info@sonopath.com

SEX

Male Neutered

AGE

3

WEIGHT

88lbs

INTERPRETED BY

Maggie Machen Lamy,
DVM, DACVIM
(Cardiology)

**IMAGING
PERFORMED BY**

HOSPITAL NAME

Mass Veterinary
Services

REFERRING VET

Dr. Masloski

INVOICE

31443

DATE

6/20/23